



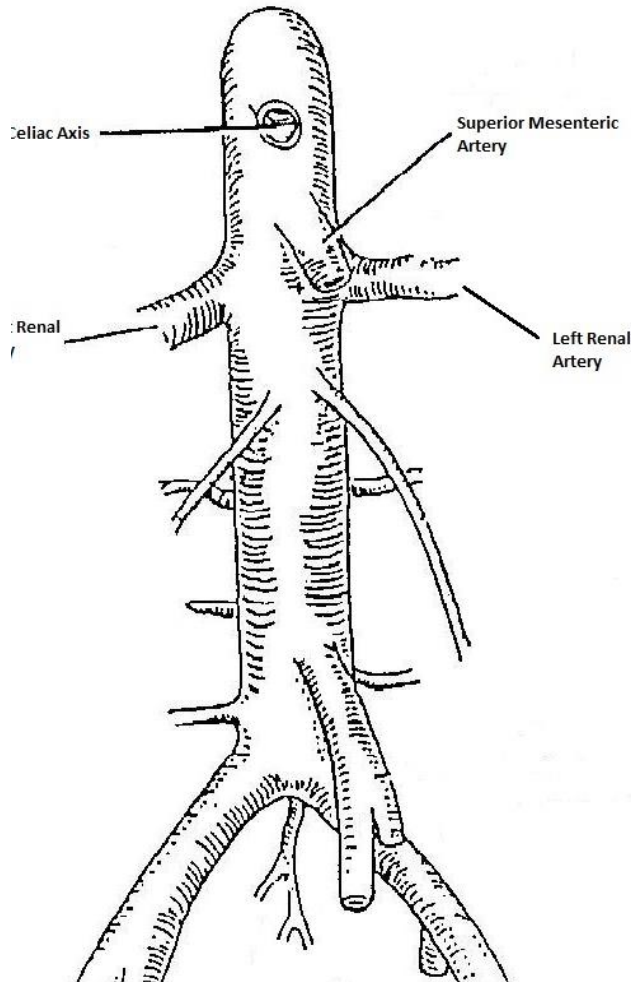
CARDIORISK AAA SCREENING

Patient Name: PETHAL, ROBERT Date: 12-08-2023

DOB: 08/18/1949 Sex: M

Referring Provider: SCOTT BELL

Vascular Technician: MICHELE WALTERS



Aorta Prox

N/V cm Trans X N/V cm AP

Aorta Mid

2.2 cm Trans X 2.3 cm AP

Aorta Distal

2.1 cm Trans X 2.3 cm AP

Comments: There was limited visibility of the Abdominal Aorta due to overlying bowel gas. Unable to exclude the possibility of an Abdominal Aortic Aneurysm in the non-visualized portion(s) of the Abdominal Aorta. There was a small amount of calcified plaque identified in the Abdominal Aorta. Suggest future abdominal ultrasound imaging be attempted early in the day, with strict NPO status of 6-8 hours and consider OTC gas medication.



